

Low back pain: Treatment of forward and backward sacral torsions using counterstrain technique

SUSAN CISLO, DO
MAURICE A. RAMIREZ, ABD
HAROLD R. SCHWARTZ, DO

The sacral foramen tender points are newly identified, specific indicators of somatic dysfunction. The use of counterstrain to release these tender points and relieve the associated somatic dysfunction is a safe, specific, and nontraumatic means of treating any patient even in the presence of illness or acute trauma. These new tender points and their releases provide a means of treating sacral torsions with counterstrain.

(Key words: Counterstrain technique, osteopathic manipulative treatment, sacral torsions, tender points, low back pain)

Counterstrain is a nontraumatic, indirect technique that relieves somatic dysfunction by positional release.¹⁻⁶ Low back pain is sacral or lumbar pain or both with or without sacroiliac pain and with or without radicular pain.⁶ Counterstrain, introduced and characterized by Jones,² has been used in treating acutely ill inpatients⁴ as well as outpatients.^{2,3,6} The key to positioning of the body is a decrease in tension and tenderness at tender points. Jones,^{2,3} Schwartz,⁴ and Ramirez⁶ have re-

ported that tender points are empirically associated with sudomotor changes, such as local temperature differences, sweating, erythema, or blanching of the skin over the tender point.^{3,4,6} The other features of tender points are documented in the literature.^{2-4,6} This article describes four previously undocumented sacral foramen tender points and their positional release with counterstrain manipulation.

Sacral torsions are named according to the direction in which the anterior aspect of the sacral base rotates around an oblique axis.⁷ Thus, a torsion in which the sacrum rotates left on a left oblique axis is named a left-on-left sacral torsion. Similarly, a torsion in which the sacrum rotates right on a left oblique axis is named a right-on-left sacral torsions.^{5,7} By convention, left-on-left and a right-on-right sacral torsion are forward torsions, whereas right-on-left and left-on-right torsions are backward torsions.^{5,7} The differentiation of forward and backward torsions is based on the lumbar spring test. The spring test is positive when no anterior motion can be induced at the lumbosacral junction. Backward torsions are associated with a positive spring test; forward torsions, with a negative spring test.^{5,7}

The sacral foramen tender points

The first sacral foramen tender point was observed in a patient who was first seen with chronic low back pain and a recurrent left-on-left sacral torsion. Diagnosis of the pelvic and

Dr Cislo is a resident, Doctors Hospital, Columbus, Ohio; Mr Ramirez is an osteopathic medical student, University of Osteopathic Medicine and Health Sciences College of Osteopathic Medicine and Surgery, Des Moines, Iowa; and Dr Schwartz is in private practice in Columbus, Ohio.

Reprint requests to Susan Cislo, DO, Doctors Hospital, North, 1087 Dennison Ave, Columbus, OH 43201-3496.

lumbar spine problems were diagnosed by the use of tender points. Treatment with counterstrain technique did not correct the torsion or relieve the pain. Muscle energy techniques were applied but provided no long-term relief, and the positions required for these techniques were uncomfortable for the patient. Examination of the sacrum revealed a tender point over the left second sacral foramen well below the location of the PS-1 sacral base posterior tender point.⁶ On the basis of a review of the literature,^{3,4,6,7} we decided that this was a previously unrecognized counterstrain tender point.

Recurrence of the patient's low back pain led us to test various release positions for the new tender point in an attempt to alleviate the patient's sacral torsion. In the 10 weeks following this initial encounter with the sacral foramen tender point, we examined every patient with a sacral torsion for tender points over the sacral foramens. All the patients demonstrated tenderness at one of the sacral foramens ipsilateral to the engaged oblique axis.

The names for the tender points are derived from their anatomic positions on the sacrum. Collectively, we refer to these tenderpoints as the sacral foramen tender points to differentiate them from tender points on the lateral borders of the sacrum^{3,4} and the medial sacral tender points.⁶ The tender points are located over sacral foramens bilaterally (Figure).

Clinically, these tender points are located by their positions relative to the posterior superior iliac spines. The most cephalad tender point is 1.5 cm directly medial to the apex of these spines. Each successively numbered sacral foramen tender point is approximately 1 cm below the preceding tender point location.

Using the sacral foramen tender points

Initially, we attempted to base our diagnosis on the sacral foramen tender points; however, we could not differentiate between forward and backward torsions with this method. For this reason, we begin our treatment with a mechanical evaluation of the sacrum,⁷ defining the presence of a sacral torsion on the basis of this evaluation. We then palpate all four foramens on the side of the sacrum ipsilateral to the involved sacral axis and treat the most sensi-

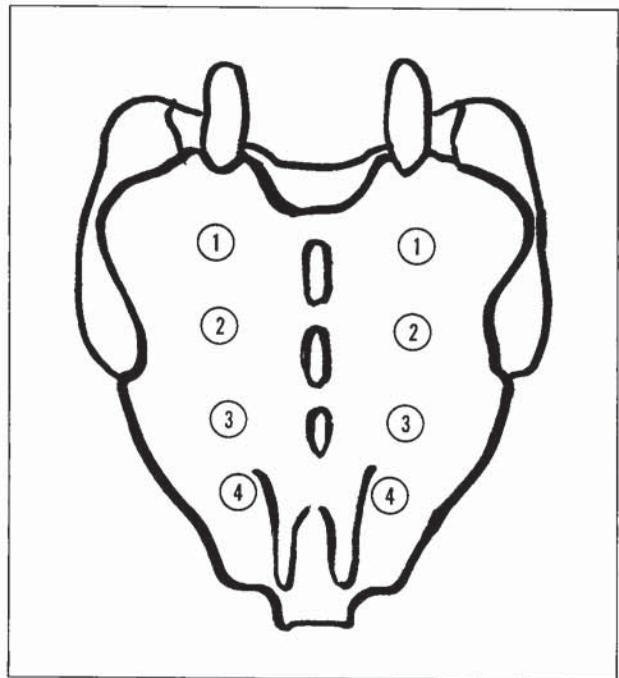


Figure. Positions of sacral foramen tender points: 1, sacral foramen 1 (SF-1); 2, sacral foramen 2 (SF-2); 3, sacral foramen 3 (SF-3); and 4, sacral foramen 4 (SF-4).

tive point. The procedure is rapid because of proximity of the tender points to one another and to the bony landmarks used in the structural examination of the pelvis.

The release for these tender points is straightforward and performed with the patient prone. All sacral foramen tender points are treated with the physician seated on the side of the patient contralateral to the tender points. The leg of the patient contralateral to the tender point is abducted 30 degrees and slightly flexed at the hip so that the patient's leg rests on the physician's lap with the patient's knee extended. The physician applies pressure to the ilium contralateral to the tender point. Pressure on the ilium is directed anteriorly, applied by the physician's forearm 1 inch lateral to the patient's posterior superior iliac spine. Regardless of the level of the foramen, all left axis torsions, both forward and backward, have responded to the same treatment position. Similarly, all right axis torsions have responded to a single technique.

The amount of pressure on the ilium, degree of flexion, and degree of abduction of the patient's hip should be that amount necessary

(continued on page 259)

to relieve between 70% and 75% of the initial tenderness in the tender point. The requirement for a 70% to 75% reduction in tenderness is a standard measurement of the accuracy of positioning in counterstrain technique.^{2-4,6,7} We have found the oral analogue system described by Schwartz⁷ and by Ramirez⁶ to be especially efficient for determining the residual tenderness at a given tender point. In this system, the original degree of tenderness is defined as "a dollar's worth of pain."⁶ The release position is "fine tuned" until the patient, when asked, reports that less than "30 cents' worth of pain" remains.⁶ The physician keeps a finger on the site of the tender point, without applying pressure, to mark the tender point's location. The release position is held for 90 seconds.^{2-4,6}

Comment

These newly identified tender points and their releases augment the treatment of sacral torsions. The counterstrain technique can be learned and competently practiced by any licensed physician who is familiar with the basic theory and positions for release of the diagnosed tender points. This basic level of knowledge may be obtained by reading Jones's *Strain and Counterstrain*,³ which is available for purchase from the American Academy of Osteopathy. Schwartz's article on counterstrain in hospital inpatients⁴ also addresses many important aspects of counterstrain di-

agnosis and treatment. Formal training in the use of counterstrain may be obtained at continuing medical education programs regularly offered at Doctors Hospital, North in Columbus, Ohio, as well as at several other sites.

Counterstrain, like all medical treatment, requires an intelligent diagnosis prior to treatment. With practice and experience, the discriminating physician should be able to localize the area of dysfunction using sudomotor changes as a guide, diagnose the specific tender points that require treatment, and accomplish the treatment quickly within a standard office visit.

1. Greenman PE: Models and mechanisms of osteopathic manipulative medicine (CME article). *Osteo Med News* 1987;4:1-20.
 2. Jones LH: Spontaneous release by positioning. *The DO* 1964;4:109-116.
 3. Jones LH: *Strain and Counterstrain*. Newark, Ohio, American Academy of Osteopathy, 1981.
 4. Schwartz HR: The use of counterstrain in an acutely ill in-hospital population. *JAOA* 1986;86:433-442.
 5. Glossary Review Committee, Educational Council on Osteopathic Principles: Glossary of osteopathic terminology. *1990 AOA Yearbook and Directory of Osteopathic Physicians*. Chicago, American Osteopathic Association, 1991.
 6. Ramirez MA, Haman J, Worth L: Low back pain: Diagnosis using six newly discovered sacral tender points and treatment with counterstrain. *JAOA* 1989;89:905-913.
 7. Mitchell FL, Moran PS, Puzzo HA: *An Evaluation and Treatment Manual of Osteopathic Muscle Energy Procedures*. Valley Park, Mo, Mitchell, Moran and Puzzo, Associates, 1979.
- Hollinshead WH, Rosse C: *Textbook of Anatomy*, ed 4. Philadelphia, Harper & Row Publishers Inc, 1985.