

# The use of counterstrain in an acutely ill in-hospital population

HAROLD R. SCHWARTZ, D.O., FAAO  
Columbus, Ohio

---

**The counterstrain method of osteopathic manipulative treatment, which is discussed in detail, uses tender points for specific diagnosis of each area of somatic dysfunction. Because somatic dysfunction may be a part of, contribute to, or result from conditions for hospitalization, this method has wide application.**

---

Despite the increase in the number of admissions to osteopathic institutions and the increase in the in-hospital services of osteopathic medicine, manipulative treatment of hospitalized patients is underutilized.

This paper describes the use of counterstrain technique for specific osteopathic diagnosis and manipulative treatment of bed-bound, acutely ill patients in the medical, surgical, obstetric, and pediatric services. This specific, nontraumatic method of manipulative care can be used for critically ill patients who are not able to cooperate because of their physical condition or because they are attached to various hospital-supportive devices, such as multiple intravenous and subclavian taps, monitors, or various types of catheters. Postsurgical patients who have undergone gastrotomy or cystotomy have been treated. Also, this would be an ideal method for the postoperative mobilization of the respiratory module (all dysfunctions of mechanical components of respiration, including the clavicle, ribs, sternum, and anterior and posterior vertebral segments, as well as the diaphragm).

## The use of counterstrain

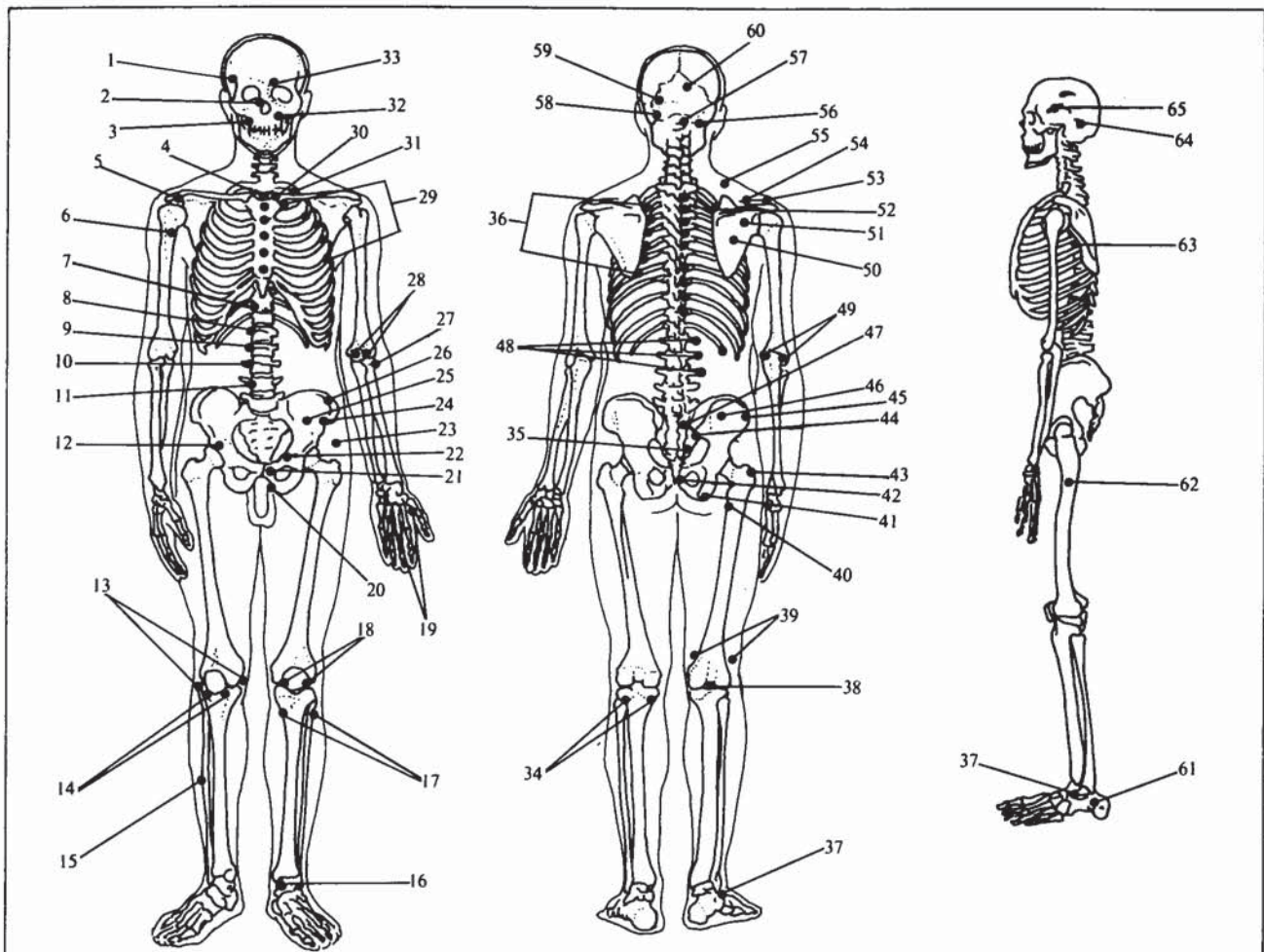
The counterstrain method of osteopathic manipulative treatment was first described by Jones.<sup>1</sup> This method utilizes tender points for the specific diagnosis of each area of somatic dysfunction. The tender point is a discrete, approximately pea-sized bundle or swelling of fascia, muscle tendons, con-

nective tissue, and nerve fibers, as well as some vascular elements. Generally, but not always, pressure on the tender point will cause pain at a site distant to the point itself. There are specific tender points for each area of somatic dysfunction. Figure 1 lists and locates the most frequently seen tender points. Because they have been catalogued by Jones,<sup>1,2</sup> they will be referred to as Jones' points. There is a resemblance to the reflex points described by Chapman in 1926,<sup>3</sup> and the myofascial trigger point as first described by Travell<sup>4</sup> in 1949. Somatic-dysfunction-related Jones' points are constant from patient to patient regardless of age or sex.

In using counterstrain technique, the Jones' point is not treated; the finger does not apply pressure on the point, as is the case with acupuncture. Utilization of the Jones' point is for diagnosis and monitoring of therapeutic effectiveness during positioning. The diagnosis is accurate and specific in its relationship to somatic dysfunction. The location of the Jones' point of dysfunction of the posterior first lumbar vertebra on the left is different and cannot be mistaken for dysfunction of the second lumbar vertebra on either the left or the right. As the body is positioned to remove pain from the Jones' point, resolution of the specific area of somatic dysfunction begins. To ensure correction of the dysfunction, it is usually necessary only to maintain the position a minimum of 90 seconds. It is difficult to conceive that a procedure that is this easily administered can be so effective. The difference between counterstrain and other therapies that involve the use of a tender point is that the other methods invade the point itself (for example, the needle in acupuncture, the injection of lidocaine into the tender point, or the use of pressure or ultrasound to destroy the tender point).

When the body is positioned in such a way as to remove pain from the Jones' point, a characteristic feel of the soft tissues becomes evident to the examining finger on the point. This has been described as a "sudden release," a "wobble," a "give," or a "melting away." A profound change occurs in the tissues under the palpating finger. With just a very small increment of positional change, the Jones' point seems to melt away. The clinical importance of the Jones' point may be directly proportional to





**LOCATIONS OF TENDER POINTS**

- |                                           |                                            |                                      |
|-------------------------------------------|--------------------------------------------|--------------------------------------|
| 1. Squamosal                              | 24. Anterior first lumbar                  | 44. Lower-pole fifth lumbar          |
| 2. Nasal                                  | 25. Iliacus                                | 45. Fourth lumbar                    |
| 3. Masseter-temporomandibular             | 26. Anterior twelfth thoracic              | 46. Third lumbar                     |
| 4. Anterior first thoracic                | 27. Radial head                            | 47. Upper-pole fifth lumbar          |
| 5. Anterior acromioclavicular             | 28. Medial and lateral coronoid            | 48. Upper lumbar                     |
| 6. Latissimus dorsi                       | 29. Depressed upper ribs                   | 49. Medial and lateral olecranon     |
| 7. Anterior seventh thoracic              | 30. Anterior eighth cervical               | 50. Third thoracic shoulder          |
| 8. Anterior eighth thoracic               | 31. Anterior seventh cervical              | 51. Lateral second thoracic shoulder |
| 9. Anterior ninth thoracic                | 32. Infraorbital nerve                     | 52. Medial second thoracic shoulder  |
| 10. Anterior tenth thoracic               | 33. Supraorbital nerve                     | 53. Posterior acromioclavicular      |
| 11. Anterior eleventh thoracic            | 34. Extension ankle (on gastrocnemius)     | 54. Supraspinatus                    |
| 12. Anterior second lumbar                | 35. High flare-out sacroiliac              | 55. Elevated first rib               |
| 13. Medial and lateral meniscus           | 36. Elevated upper ribs (on rib angles)    | 56. Posterior first cervical         |
| 14. Medial and lateral extension meniscus | 37. Lateral ankle                          | 57. Inion                            |
| 15. Tibialis anticus medial ankle         | 38. Posterior cruciate ligament            | 58. Left occipitomastoid             |
| 16. Flexion ankle                         | 39. Anterior cruciate ligament             | 59. Sphenobasilar                    |
| 17. Medial and lateral hamstrings         | 40. Posterior medial trochanter            | 60. Right lambdoid                   |
| 18. Medial and lateral patella            | 41. Also posterior medial trochanter       | 61. Lateral calcaneus                |
| 19. Thumb and fingers                     | 42. Coccyx (for high flare-out sacroiliac) | 62. Lateral trochanter               |
| 20. Low-ilium flare-out                   | 43. Posterior lateral trochanter           | 63. Subscapularis                    |
| 21. Anterior fifth lumbar                 |                                            | 64. Posteroauricular                 |
| 22. Low ilium                             |                                            | 65. Squamosal                        |
| 23. Anterior lateral trochanter           |                                            |                                      |

Fig. 1. Location of myofascial tender (Jones') points (Adapted from Jones<sup>2</sup> by permission).



the amount of pain generated by stimulation.

Somatic dysfunction may be a part of, contribute to, or result from many conditions that cause hospitalization. The normalization of this dysfunction is necessary and desirable for the most rapid return of the patient to a state of health. On the medical service at James A. Taylor Hospital, a 50-bed, acute-care general hospital with a 38-bed intermediate-care facility attached, counterstrain is the primary manipulative method used by the service of osteopathic medicine. It is routinely used for adjunctive treatment of myocardial infarction, congestive heart failure, respiratory failure, pneumonia, bronchitis, and asthma.

The surgical department utilizes the service for preparation of the patient for operation by normalizing the respiratory module and for treatment of postoperative ileus. It may also be used for the correction of hospital-acquired positional pain, such as may occur after spinal anesthesia, when the patient may be too rapidly moved from his side to his back, or following a too-rapid return from the lithotomy position after a perineal procedure.

Counterstrain technique can also be used to differentiate between disease and a functional disorder. For example, a patient with an anterior myofascial Jones' point at T11 may have appendicitis or somatic dysfunction. (This point is located approximately 1 inch from the midline and approximately 2 inches below the level of the umbilicus). The Jones' point is then normalized with the counterstrain procedure. If the pain returns to the Jones' point as well as the abdomen within a very short period of time, acute appendicitis would be strongly suspected. Conversely, if the pain were relieved and the patient appeared to be markedly improved, there would be little doubt that appendicitis was not involved. This technique also can be used to diagnose between myocardial infarction and acute costochondritis, with the latter being very amenable to treatment of left anterior interspace dysfunction. Literally thousands of hospital days could be saved by judicious osteopathic examination for interspace dysfunction and appropriate counterstrain treatment.

The discussion of specific areas of treatment will refer to the diseases mentioned; however, this represents a small portion of the disease spectrum that is compatible with counterstrain technique.

Anterior lumbopelvic dysfunction has been implicated in the residual pain of the delivery process and has been given special emphasis in the obstetric service. Whether these dysfunctions are a corollary of the parturient habitus or result from delivery cannot be ascertained and should be a subject for further study.

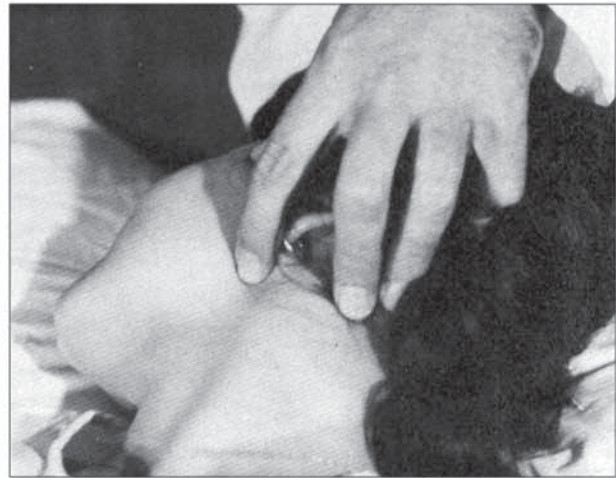

Fig. 2. Location of Jones' point for anterior C1. Note the position of the Jones' point in the groove between the styloid process and the angle of the mandible.

Jones has stated that all counterstrain positions are amenable to the bed-bound patient.<sup>5</sup> Without exception, this observation has been found to be valid. In this paper, an outline of the most common Jones' points and a description of the positions for normalizing them by counterstrain are presented. The positions have been synthesized from the writings,<sup>1,2</sup> teachings, and individual adaptations of Jones.

In general, two motions are required to normalize dysfunction with counterstrain technique: (1) Gross movement is required to place the parts of the body to an approximate position; and (2) it is then necessary to reposition or "fine tune" the parts involved to remove the pain from the Jones' point.

Dysfunctions that produce Jones' points on the anterior surface of the body require a forward-bending position for correction. Conversely, dysfunctions that produce Jones' points on the posterior aspect of the body will respond to backward bending for correction.

The pain caused by the palpating finger on the Jones' point is reduced in a few seconds if the correction position is proper. Generally, 20 seconds is adequate time for the pain to subside (two-thirds relief is acceptable); otherwise, the position must be altered for a better response.

## Areas of treatment

### *Cervical area*

**Anterior cervical segments.** The anterior cervical Jones' points are located on or about the tips of the transverse process of the vertebrae. There are exceptions. For example, there are two Jones' points for the anterior C1; the first is located in a



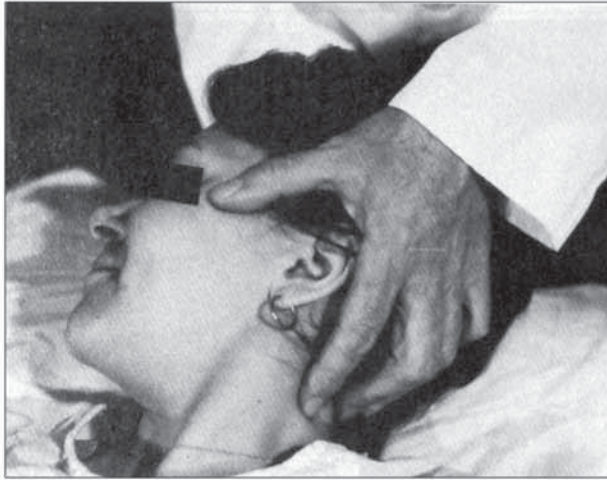


Fig. 3. Location of Jones' point for anterior C3 on the left. Note position for correction (flexion of the neck forward and approximately 45 degrees' rotation away from the Jones' point).

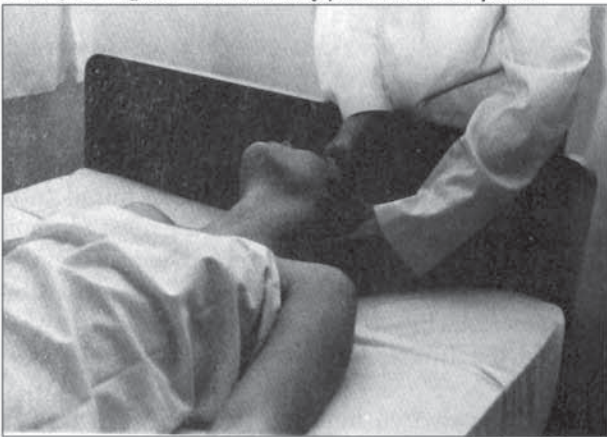

Fig. 4. Location of the first posterior C1 Jones' point on the left. Note the general position for correction (rotation of the head away from the Jones' point and marked hyperextension of the neck, as accomplished by downward pressure on the forehead).

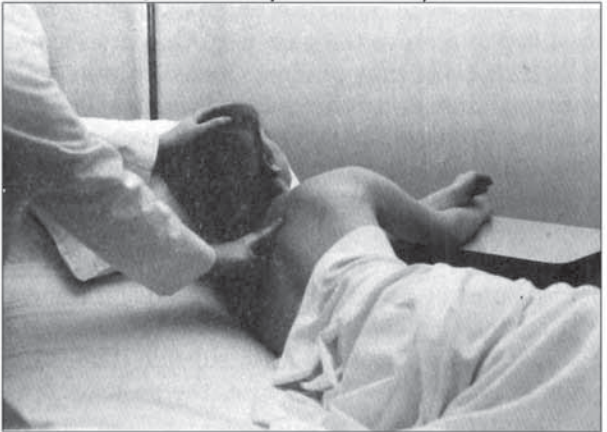


Fig. 5. Position for correction of posterior C5 dysfunction on the right.

groove between the styloid process and the angle of the mandible (Fig. 2). This area is easily nor-

malized by rotating the head away from the side of the dysfunction. Fine tuning is accomplished, if necessary, by side bending the head slightly downward on the neck. The second Jones' point for anterior C1 dysfunction is located approximately 1/2 inch anteriorly to the angle of the mandible. This is treated as anterior C3 dysfunction. The head is placed in a forward-bending position, with approximately 45-degree rotation away from the Jones' point (Fig. 3).

The remaining anterior dysfunctions of the cervical vertebrae are treated by locating the Jones' point and positioning the head in a forward-bending rotation position of the neck so as to take the pain out of the point. In general, the higher the Jones point, the more rotation away from the point and the less forward bending that is needed, while the lower the Jones' point the more forward bending and the less rotation that is required. Thus, the patient may be treated in bed for anterior cervical dysfunctions without difficulty.

**Posterior cervical segments.** The cervical posterior Jones' points are situated on or about the spinous processes. Dysfunctions with Jones' points in the posterior portion of the body are generally treated by backward bending. There are also two Jones' points for posterior C1. The first is found in the occipital groove between the occiput and the posterior arch of C1, and the second is located either on or just laterally to the inion. In the first instance, the head should be slightly extended and rotated away from the Jones' point. Some slight downward pressure is then placed on the forehead of the patient to maximize the extension position (Fig. 4). The inion dysfunction is treated by placing the head/neck into acute forward bending, with the chin almost touching the trachea.

Posterior dysfunctions of the cervical area are treated by taking the pain out of the Jones' points that are present on or about the spinous process of the vertebrae. This is accomplished by extending the head on the neck. This procedure can be used with ease for the bed-bound patient if he/she can be turned on the side. The preferred method is to place the side of the lesion away from the pillow so that fine tuning can be performed with slight side bending and rotation of the chin toward the side of the dysfunction (Fig. 5).

The posterior C3 dysfunction can be treated with either forward or backward bending. The posterior C8 Jones' point, which is located on the posterior portion of the transverse process of C7, can also be treated by slight extension, marked side bending, and rotation away from the Jones' point.



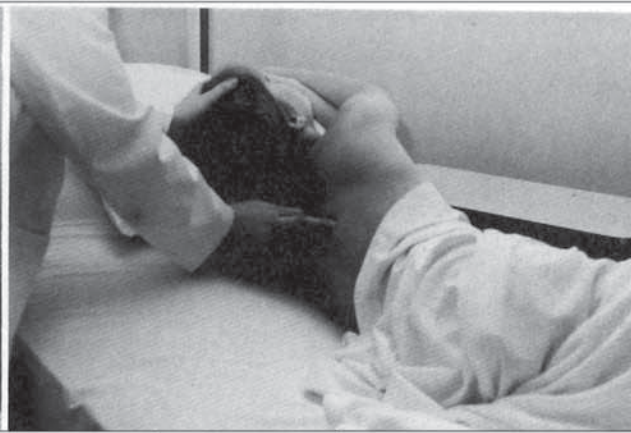
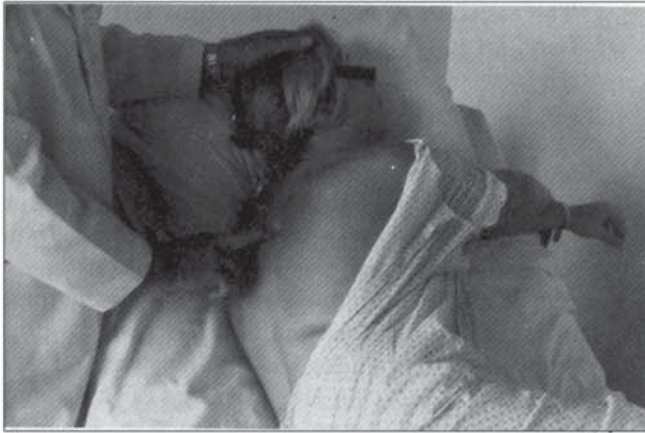

Fig. 6. Location of posterior T3 Jones' point on the right and position for correction. Fig. 7. Location of the Jones' point for posterior T7 on the right and position for correction.

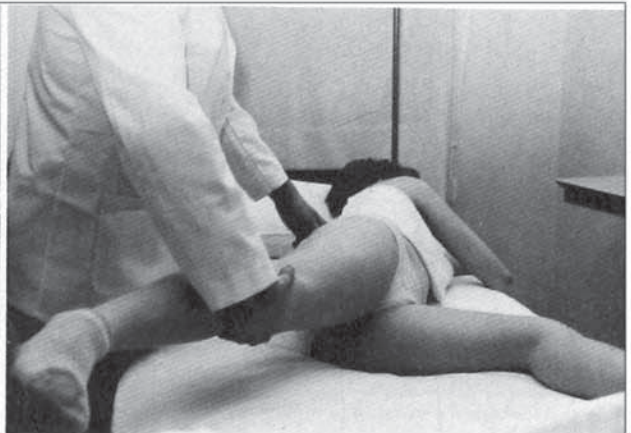
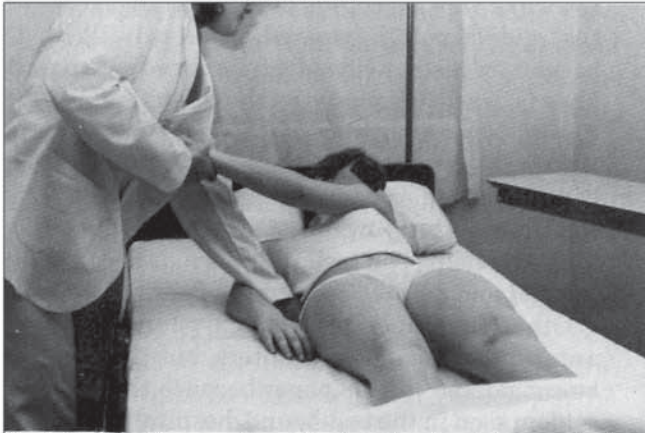

Fig. 8. Position for correction of dysfunctions involving myofascial Jones' points for T9 through T12. This dysfunction may just as easily be treated in Fowler's position. Fig. 9. The Jones' point for posterior L1 and L2 are located directly on the transverse processes of the respective vertebrae. Note the reverse scissor-like position for correction. The leg further may be supported by the physician's knee.

### Thoracic/lumbar areas

**Posterior thoracic segments.** Posterior thoracic dysfunctions are treated in the same way as posterior cervical disorders. The Jones' points for the upper thoracic vertebrae usually are located either on or close to the spinous process bilaterally or on the paravertebral muscle mass. The further downward the segment, the closer the trigger comes to the transverse process. Treatment (direct backward bending of the spine to this level) is easily administered if the patient can be placed on the side. When possible, the patient's arms are held at the level of the shoulders in an easy resting position against the bed or another pillow (Fig. 6).

For the middle four segments (T5-8), the arms are elevated above the head (Fig. 7). The lower four segments (T9-12) are treated with the patient in a supine position. The hand on the side opposite that of the lesion is grasped, and the arm is drawn across the chest so that the opposing shoulder makes a 30-

to 45-degree angle with the bed (Fig. 8). The dysfunction is then fine tuned until the characteristic release of correction is palpated.

When the patient cannot be turned on the side or when extension of the spine is uncomfortable, the same technique that is described for the treatment of the lower four segments may be substituted for the positions shown in Figures 6 and 7.

**Posterior lumbar segments.** The posterior Jones' points for L1 and L2 lie over the tips of the transverse process of their respective vertebrae (Fig. 9). The Jones' point for L3 is found approximately 1/2 inch below the margin of the ilium, and about 3 inches laterally to the posterior superior iliac spine, while the Jones' point for L4 is located approximately 1 1/2 inches further laterally (following the contour of the ilium). There are three Jones' points for L5. The first, which is called the upper pole, is located medially between the spinous pro-



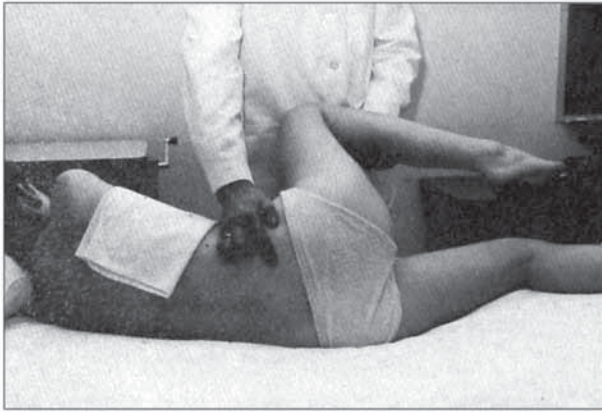


Fig. 10. Treatment of middle-pole L5 dysfunction.

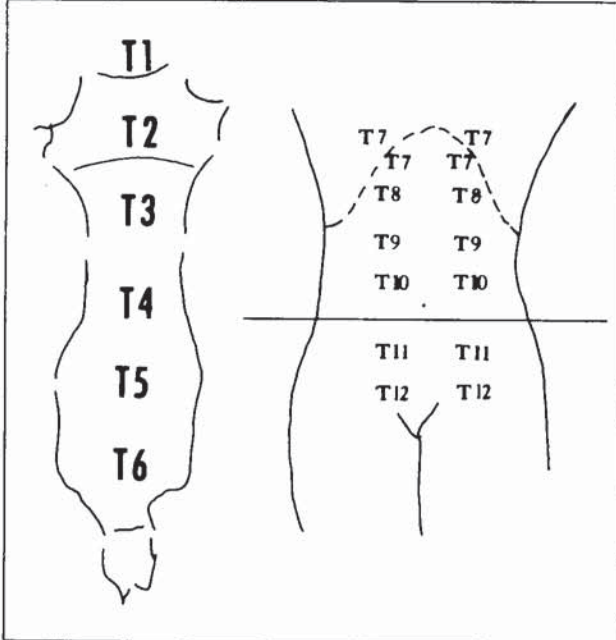


Fig. 11. Location of the first anterior thoracic Jones' points. Fig. 12. Location of Jones' points for the anterior T7 to T11.

cess of L5 and the spinous process of the first sacral segment. The second, the middle pole, is located in the superior sulcus of the sacrum, and the third, the lower pole, is located midway on the body of the sacrum. These Jones' points are traditionally treated with the patient in the prone position; however, this can just as easily be done with the patient on his/her side. If the patient is prone, the physician stands on the opposite side of the dysfunction, grips the leg an inch or two above the knee, and brings it toward him/her in a scissor-like maneuver. This is done in a similar manner when the patient is lying on the side. Stand facing the back of the patient, hold the leg above the knee, and draw the leg toward the person until the trigger is felt to start to give. Fine tuning is accomplished by gently raising or lowering the leg (Fig. 9).

The routine treatment of dysfunction involving L3 and L4 has the patient prone and the operator on the side of the dysfunction. The physician would place his/her thigh under the patient's thigh and extend the leg. Fine tuning would be achieved by abducting the leg and rotating the foot outward. The same position can be obtained with the patient lying on the side, with the dysfunctioned side up. Using a chux-type of pad, put the foot on the bed just behind the patient's lower leg, with the upper leg elevated and placed on the thigh. Fine tuning is accomplished by moving the thigh forward or backward and by rotating the foot. For L5, the upper pole is handled in the same way as L1 and L2 dysfunctions (Fig. 9). The lower pole is treated in the same way except for the fine tuning. However, the middle pole is treated differently. With the patient on his/her side (dysfunctioned side up), the knee is flexed and placed on the thigh (Fig. 10). Fine tuning is accomplished with slight movement of the thigh either toward the head or the foot of the bed. Elevating or depressing the knee by bringing the thigh either toward or away from the patient may also help. The ipsilateral arm is dropped over the bed and pointed toward the floor.

Other Jones' points involve dysfunctions of the anterior pelvis and trochanters, but these will not be considered in this paper because they are very seldom seen in the bed-bound, hospitalized patient. For discussion of these, refer to Jones<sup>6</sup> article on spinal lesions. These positions are all readily adaptable for use on the bed-bound patient.

**Anterior thoracic segments.** If one theorizes a posterior aspect of a segmental disturbance that is called an osteopathic lesion or somatic dysfunction, there should be no logical reason why an anterior aspect of the same disturbance cannot be accepted. There are times in the treatment of a patient when the physician becomes aware that both dysfunctions are present. For example, a posterior T10 dysfunction on the right may coexist with an anterior T10 dysfunction on the right, or they may occur independently. The release that comes with the correction of these anterior dysfunctions is very evident to both the patient and the physician.

The first anterior thoracic Jones' point is located on the superior surface of the manubrium in the midline. The Jones' points for T2 through T6 lie in line approximately 1/2 to 3/4 of an inch apart (Fig. 11).

The Jones' points for the anterior T7 are bilateral and are located close to the midline and under the xiphoid process. There are also lateral anterior T7s. These are located on the costal margin close to the xiphoid process. The Jones' points for dysfunctions that involve T8 through T11 lie in the abdomi-



nal wall, approximately 1 inch lateral to the midline (Fig. 12). Using a horizontal line 1/2 inch below the umbilicus will locate the Jones' point area for T10; approximately 1 1/2 inches below that is the Jones' point for T11. The Jones' point for T12 lies on the crest of the ilium at the mid-axillary line. Approximately 1 inch or so above T10, the Jones' point for T9 can be found, and in turn, Jones' point T8 lies approximately 2 inches above that.

Corrections of anterior thoracic dysfunctions easily lend themselves to bedside techniques. These methods are simple, and the only equipment needed is a pillow and some chux-type pads. For anterior T1-6 dysfunctions, the physician need only forward bend the head on the chest, with the patient's hands and arms outstretched from the body. The lower the dysfunction, the greater the angle of flexion that is required for correction (Fig. 13).

With the finger or thumb on the Jones' point, forward bend the head on the chest until the point is felt to begin releasing. Occasionally, the head end of the bed needs to be raised or lowered. If possible, use the flexed thigh on the bed to support the head for the necessary 90 seconds. Fine tuning is done by slight rotation of the chin toward or away from the side of the dysfunction.

Treatment of the lower anterior thoracic dysfunctions, which basically is forward bending of the thoracic spine, is satisfying because of the rapid patient improvement. It is easily accomplished in the bedridden patient. Place a pillow under the buttocks of the patient to cause a space between the bed and the segment of the spine that you wish to forward bend. For example, to treat an anterior T8 dysfunction, use a fairly large pillow, or be prepared to raise the patient's thigh on the abdomen a higher distance than if you were treating a T12 dysfunction (Fig. 14).

In treating T9-12 disorders, with the patient's buttocks on a pillow, place your foot on the bed. (Be careful to avoid contamination by using a chux-type pad under your foot.) The nearest leg is placed on the thigh, the other leg is brought up, the patient's ankles are crossed, and the patient's calves are supported on the thigh. Fine tuning is performed by moving the thigh toward or away from the patient (Fig. 15).

The treatment of an anterior T12 dysfunction requires more side bending than does the other anterior thoracic dysfunction. The Jones' points for T10 and T11 may be treated from either side of the dysfunction.

**Anterior lumbar segments.** Treatment of anterior lumbar dysfunctions is equally easy. The gross positioning is the same as for anterior thoracic disorders. The anterior L1 has two Jones' points—

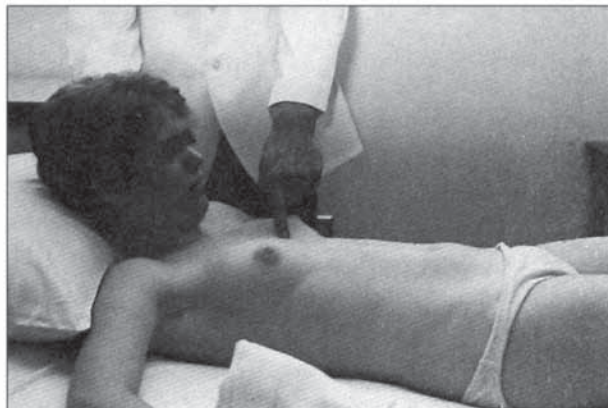


Fig. 13. Position for correction of anterior T5 dysfunction.



Fig. 14. Position for correction of anterior T8 dysfunction on the right.

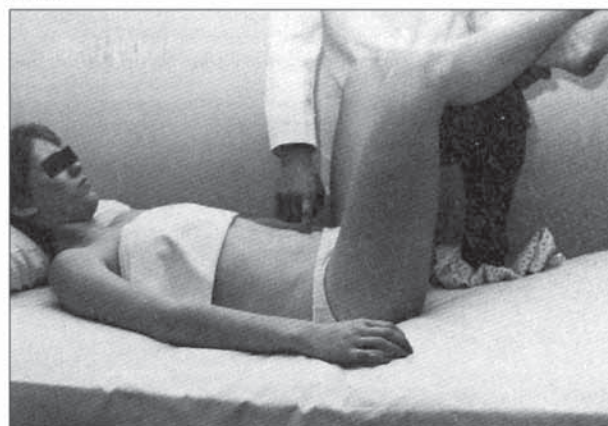


Fig. 15. Position for correction of anterior T10 dysfunction on the left.

one at the tip of the anterior superior iliac spine, and the other on the medial surface of the ilium, just medially to the anterior inferior iliac spine (Fig. 16).

The Jones' points for the anterior second lumbar vertebra are located just laterally to the anteroinferior iliac spine. Despite stimulation, it is sometimes difficult to elicit pain from the anterior L3 Jones' points, and it is very often necessary to de-



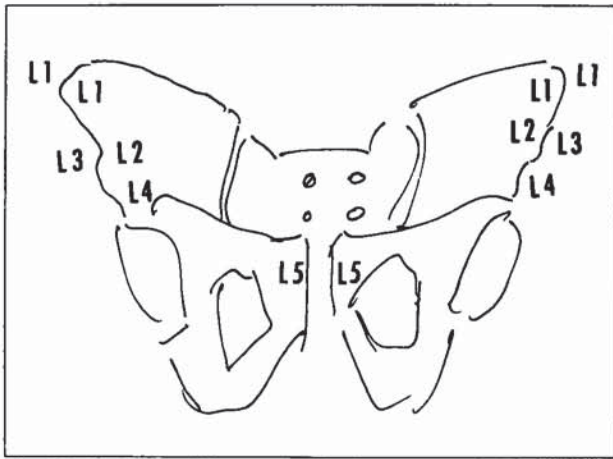


Fig. 16. Location of the anterior lumbar Jones' points.

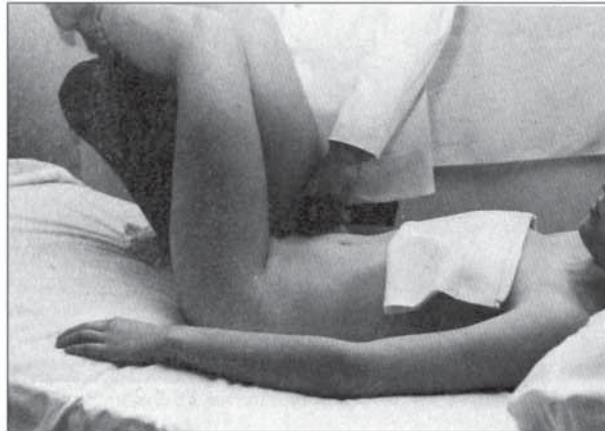


Fig. 17. Position for treatment of anterior L5 dysfunction on the right. Note the higher position of flexion of the thighs on the abdomen. It is important to remember that these dysfunctions can be bilateral.

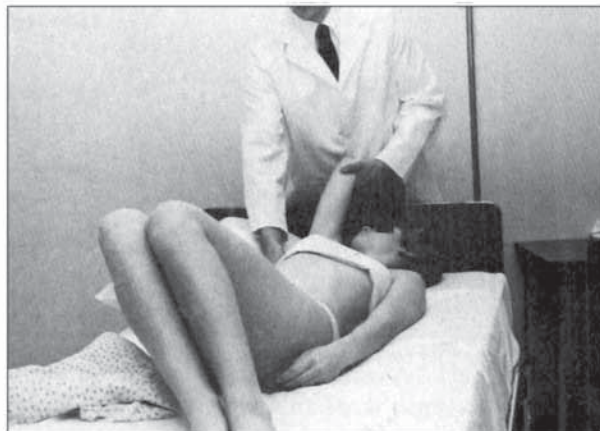

Fig. 18. Position for correction of an elevated rib.

pend on palpatory skills for its detection. The anterior L3 Jones' points are situated approximately 1/2 inch below a line connecting the second and third points, and the L4 points are found at the insertion of the inguinal ligament on the ilium. The Jones' points for the anterior L5 lumbar segment are lo-

cated directly on the body of the pubes.

The positions for treatment are very similar to those for the anterior thoracic segments, except that the knees are placed together. Also, the technique (forward bending of the thighs on the abdomen) must be done individually for each side if the dysfunction is bilateral (Fig. 17). Treatment for the L3 and L4 is similar to that for T11 and T12, in that more side bending is necessary.

**Rib dysfunction.** Treatment of the rib cage is one of the most fascinating aspects of counterstrain technique, for the ribs can be normalized as easily as they are dysfunctional. Treatment of the rib dysfunction may easily be done with the patient in bed. A depressed rib has its Jones' point at the anterior axillary line, while an elevated rib Jones' point is located posteriorly at the angle of the ribs. The scapula must be drawn away from the thorax to palpate the angles of the ribs that normally lie under it. This is accomplished by pulling the arm gently across the chest or by elevating the shoulder.

When treating rib dysfunction, stand on the side of the disorder. Because of the rapid tissue change, the palpating finger must be kept on the Jones' position as the patient's position is changed. The patient also experiences a subjective change in the sensation of pain. The knees of the patient are drawn into a flexed position; they are then allowed to move in the direction of the side of the hemithorax that has been elevated by the pillow.

In the case of the elevated rib, fine tuning is accomplished by drawing the arm or shoulder on the side of the elevation toward the head of the bed, in effect exaggerating the positional deformity (Fig. 18). For further fine tuning, turn the head toward the elevated side.

When normalizing a depressed rib, the positioning is just opposite to that used to normalize an elevated rib. The physician stands or sits on the side of the dysfunction, with one hand on the Jones' point and the other drawing the ipsilateral arm down toward the foot of the bed until release is palpated (Fig. 19).

**Interspace dysfunction.** Another area of importance is interspace dysfunction. These Jones' points are located between the insertions of contiguous ribs into the cartilages at the sternum; they are easily recognized, if not by their exquisite pain, by the closeness of the ribs to each other. The tenderness is most acute in fresh or new somatic dysfunction. The older the area of dysfunction, the less tender the myofascial Jones' point will be. However, all of the other attendant factors will be



present; for example, edema and induration of the tissues of the Jones' points will be palpable. By stimulating the Jones' points for 10 to 30 seconds, the pain will reappear just as strongly as it was when it was in the acute state.

These dysfunctions are implicated in costochondritis, the persistent chest pain of the patient who has suffered acute myocardial infarction, "atypical angina," and anterior chest wall syndrome. They are strongly implicated along with depressed and elevated ribs in restricted motion of ribs in either inspiration or expiration, and thus they contribute to the etiology and morbidity of many respiratory illnesses.

Interspace dysfunctions can be treated with the patient supine in bed. For example, if the patient has a dysfunction at the level of the 3-4 interspace on the right, place a pillow under the left hemithorax. Standing on the patient's right side, the right hand of the physician is on the patient's chest, with the finger or thumb on the interspace Jones' point (Fig. 20). The left hand is placed in such a way so that it supports the patient's head while still putting the head in approximately a 45-degree position toward the foot of the same side of the bed. If the position is correct, the pain in the Jones' point will disappear in about 30 seconds, but the position should be held for 90 seconds before the patient is slowly returned to the normal position.

### Comment

The disadvantages of counterstrain technique are few. For some patients who have been treated by more orthodox methods, it may be difficult for them to realize that they have, in fact, been treated with osteopathic manipulation. It is very difficult to use this technique in a stoic patient who denies pain and also denies feeling any change.

Approximately 25 to 30 percent of patients have some reaction to treatment, despite the ease of administration and the passive type of motion used. Occasionally, there are extensive reactions to muscle release, as there are with all types of manipulative treatment. Although these reactions are transitory, not lasting for more than a few hours, the patient should be warned of the possibility of having such a response to the treatment.

The most important advantage to the use of counterstrain technique is that positioning can be carried out for almost every patient, and the patient does not have to be cooperative to be treated.

Treatment is noninvasive and nontraumatic. It may be used on patients with fractures, as well as on postsurgical patients who have pain at the site of incision. It may also be used on patients who have osseous metastatic disease. If the part of the

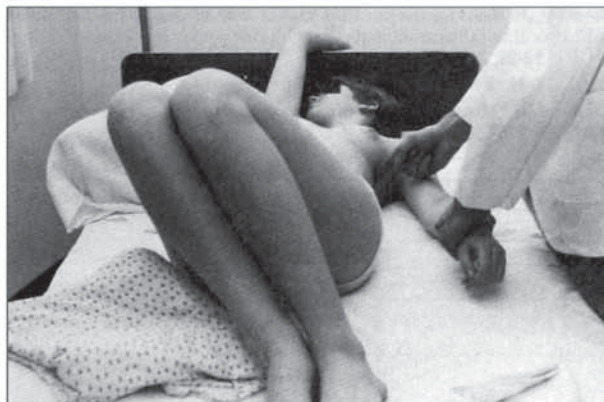

Fig. 19. Position for a depressed eighth rib on the left. Note that the patient's right arm, which is not completely seen in this picture, is elevated over the head and rests on the pillow. In some cases, the right arm may need to be held by an assistant in a traction-type position.

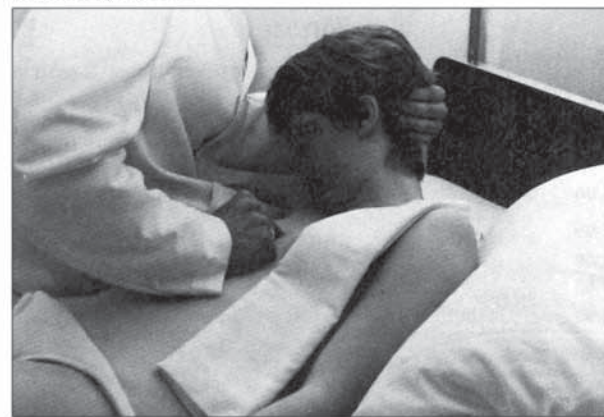


Fig. 20. Treatment of interspace dysfunction.

body that is to be treated can be moved by the patient, it can be safely treated with counterstrain technique.

If the treatment has been administered properly, the result is lasting, and it is usually unnecessary to retreat the patient on a daily basis unless there is a strong, ongoing neurosensory reflex.

The knowledgeable physician soon learns to recognize the important dysfunctions. These involve key areas, and normalizing them will often correct two or three secondary dysfunctions, thus saving time and energy for both the patient and the physician.

1. Jones, L.H.: Spontaneous release by positioning. D.O. 4:109-16, Jan 64
2. Jones, L.H.: Strain and counterstrain. American Academy of Osteopathy, Newark, Ohio, 1981
3. Owens, C.: An endocrine interpretation of Chapman's reflexes by the interpreter. Ed. 2. Chattanooga Printing & Engraving Co., Chattanooga, Tennessee, 1937



4. Travell, J.: Basis for the multiple uses of local block of somatic trigger areas. Procaine infiltration and ethyl chloride spray. Mississippi Valley Med J 71:13-21, Jan 49

5. Jones, L.H.: Personal communication

6. Jones, L.H.: Missed anterior spinal lesions. A preliminary report. D.O. 6:75-7, Mar 66

---

Accepted for publication in February 1984. Submitted as partial

fulfillment of the requirements for fellowship in the American Academy of Osteopathy.

---

Dr. Schwartz is director, Service of Osteopathic Medicine, Doctors Hospital, Columbus, Ohio.

Dr. Schwartz, Doctors Hospital, 1087 Dennison Avenue, Columbus, Ohio 43201.