

Some methods of applying counterstrain

BERKELEY BRANDT, JR., D.O.

Auburn, Washington

LAWRENCE H. JONES, D.O., F.AAO

Ontario, Oregon

These techniques are based on the fact that a stretch of a myotonic joint in the direction of maximum comfort, held for 90 seconds, will release the bind of tonic neuromuscular reflex spasm of joint somatic dysfunction.

The method is to locate a sensitive myofascial trigger relating to a specific myotonia of a joint and to stretch the involved joint into a position of comfort. This will immediately relieve the myotonia and reduce tenderness of trigger by 70 percent. The patient is passive and is maintained in this stretched position for 90 seconds, followed by *slow passive* return to neutral. The immediate relaxation of the tense muscle is palpable to an experienced operator.

This method of correcting somatic dysfunction of joints is based on the hypothesis that they are neuromuscular reflex disorders rather than mechanical impingements of joints. According to this concept, the maintaining factor of joint lesioning is a self-perpetuating strain reflex with resultant tonic muscle spasm as the only important mechanical factor. This reflex serves as a continuing source of irritation. Although healing processes are constantly at work, the condition is being continuously irritated by the persisting abnormal strain reflex, so that healing is indefinitely postponed.

These continuing abnormal strain reflexes and the resultant muscle spasm may be inhibited by passively initiating equal and opposite strains with equal and opposite strain reflexes—in counterstrains with counter reflexes. If a joint is limited in its ability to flex, it will have free ability to extend. The return to neutral must be slow and passive or the abnormal reflex will be reinstated.

Beginners can proceed with confidence in their search for the ideal position of relaxation simply by repeated identical probing and questioning of the patient as to decrease in tenderness. In time they will acquire the ability to palpate muscle relaxation and greatly accelerate location of the ideal position.

The pressure used is the degree which is expected to be less than enough to cause pain in healthy tissue. In most of the following illustrations, the finger palpates the sensitive point involved.

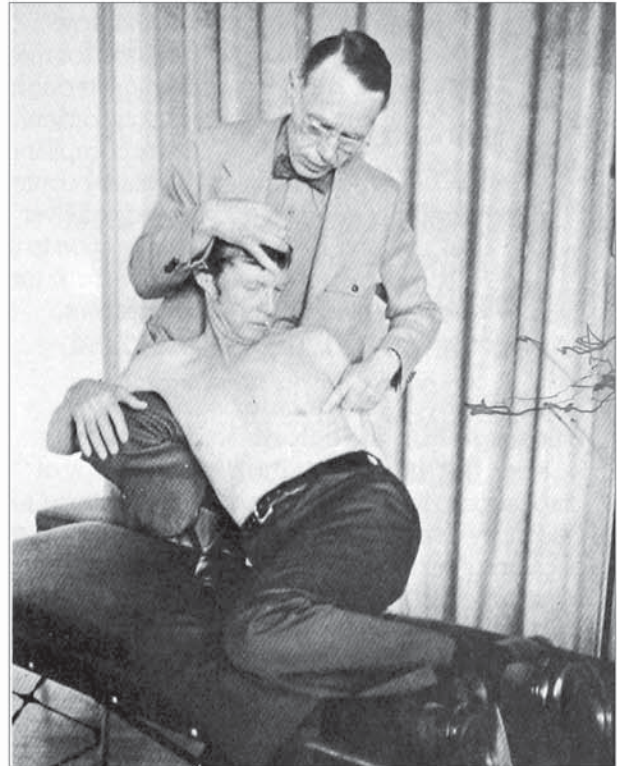


Fig. 1. Depressed 5th rib. Patient sits on table leaning off to right over operator's thigh. Release is obtained by side-bending and rotation to the left at 5th thoracic level. Release comes with adequate patient relaxation (usually 30 seconds). Myofascial trigger is in anterior axillary line on 5th rib.

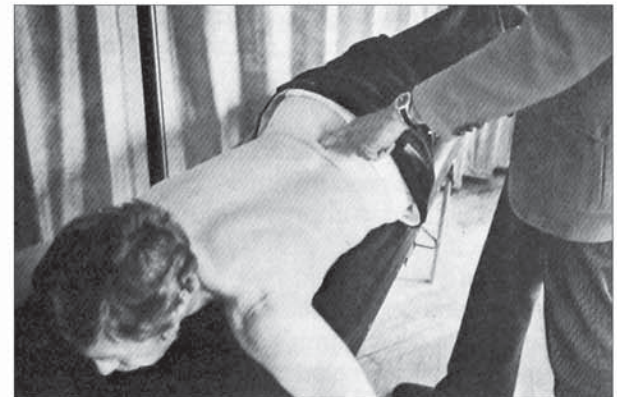


Fig. 2. Right 4th lumbar. Patient prone, operator grasps right leg just below patient's knee extending, adducting thigh and rotating left. Trigger is on upper medial edge of posterior-superior spine.

continued on page 787/43

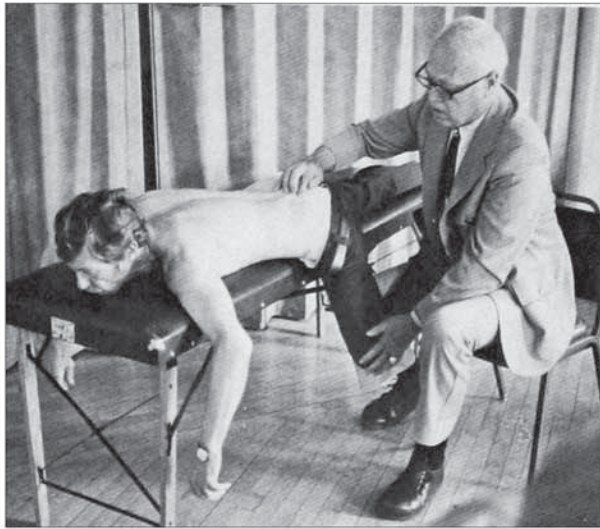

Fig. 3. Lower pole 5th lumbar left. Note that the patient's left thigh is suspended vertically over the edge of table, slight abduction. Trigger is in the saddle between posterior-superior and posterior-inferior spine of ilium. This is a lumbosacral dysfunction commonly associated with post thigh pain often mistakenly blamed upon a sacroiliac. There is frequently another trigger over upper end of medial sacral crest.

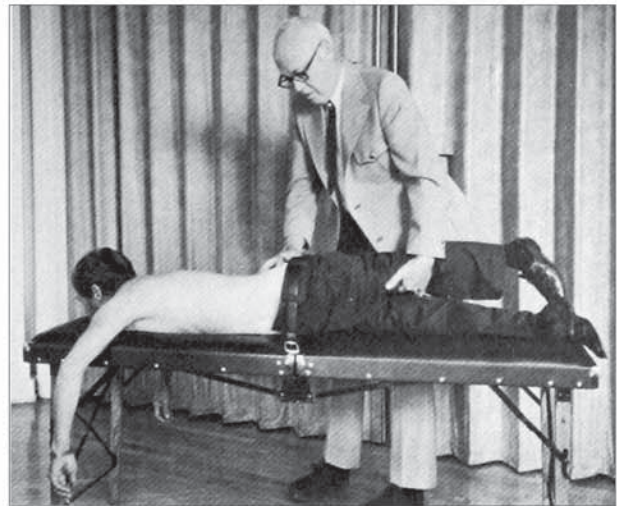


Fig. 4. Upper pole 5th lumbar left. Trigger is on spinous process and on medial surface of posterior-superior spine. Leg is extended, with slight adduction, and pelvis rotates with stretch.

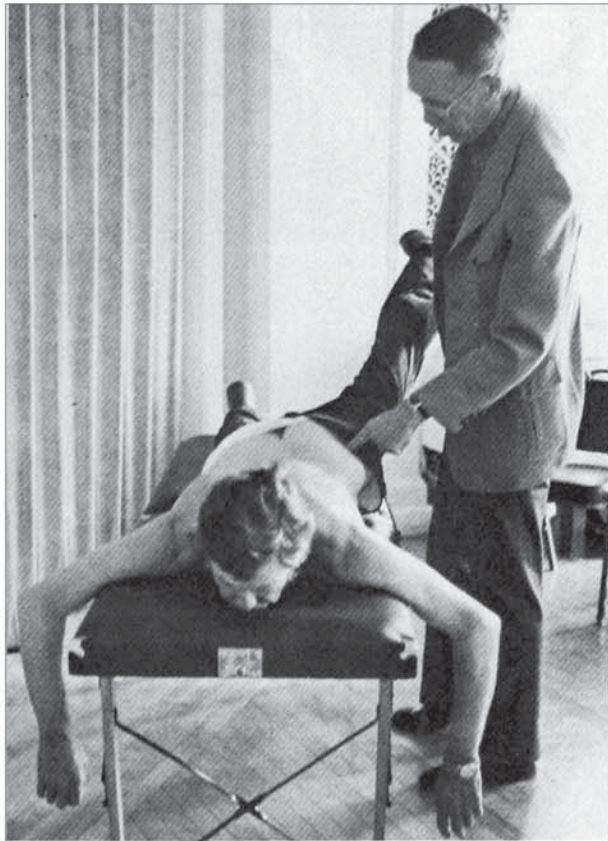

Fig. 5. Posterior trochanter. This is a common reflex neuromuscular dysfunction arising from proprioceptive nerve endings of the enarthrosis of the hip. Femur is extended, abducted, and externally rotated in acetabulum. Trigger is on posterior-superior surface of greater trochanter.

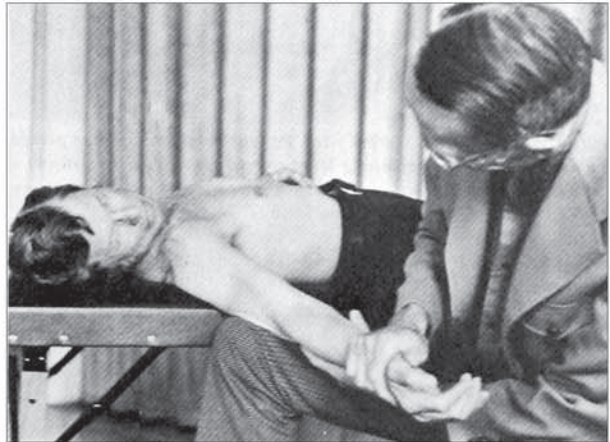

Fig. 6. Lateral olecranon. This is a reflex dysfunction of the humero-ulnar joint. It is comfortable and released in extension.

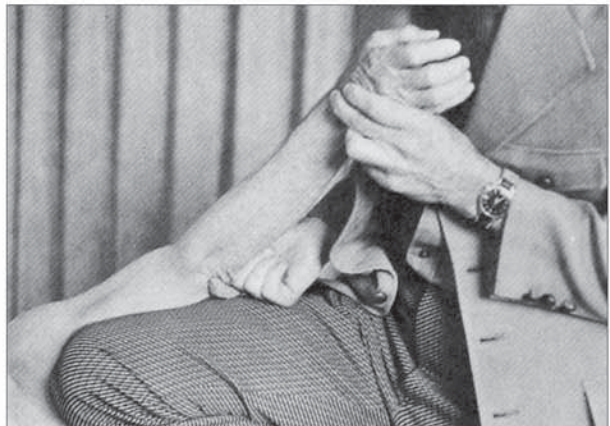

Fig. 7. Often slight abduction or adduction will be necessary to "fine-tune" it.

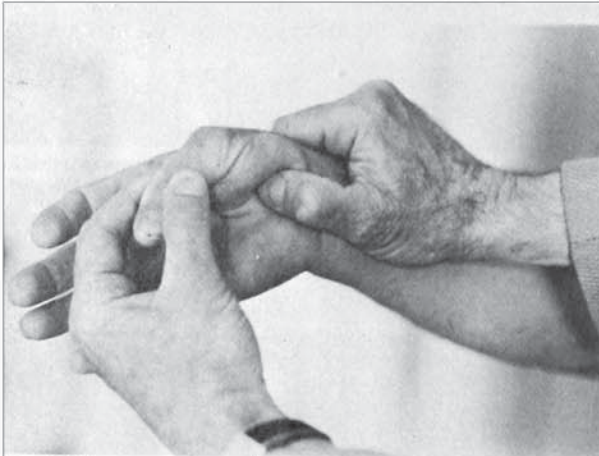


Fig. 8. First carpo-metacarpal joint. Patient complains of weak painful thumb especially when grasping large objects which require extension of the thumb. He is aware of pain in metacarpo-phalangeal joint, but dysfunction and trigger is "one joint higher." This phenomenon is common in appendicular joint dysfunctions. Thumb is flexed and twisted into opposition with palm, but not necessarily approximated. Trigger is deep in palmar surface of joint.

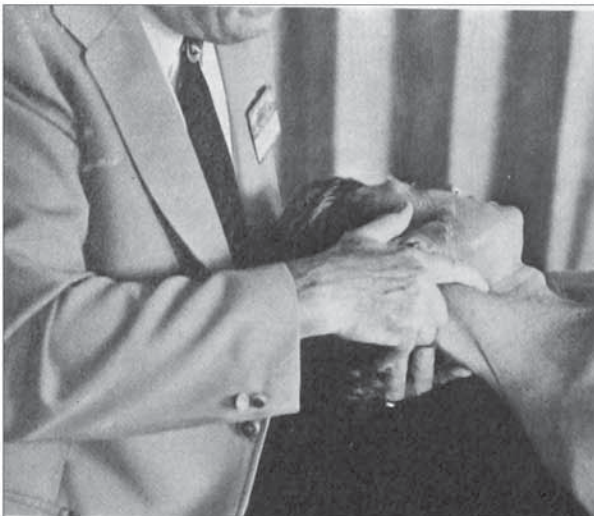

Fig. 10. Anterior 2nd cervical. Trigger is at surface tip of transverse process of 2nd cervical vertebra. Release follows rotation away from trigger side, with little bending motion.

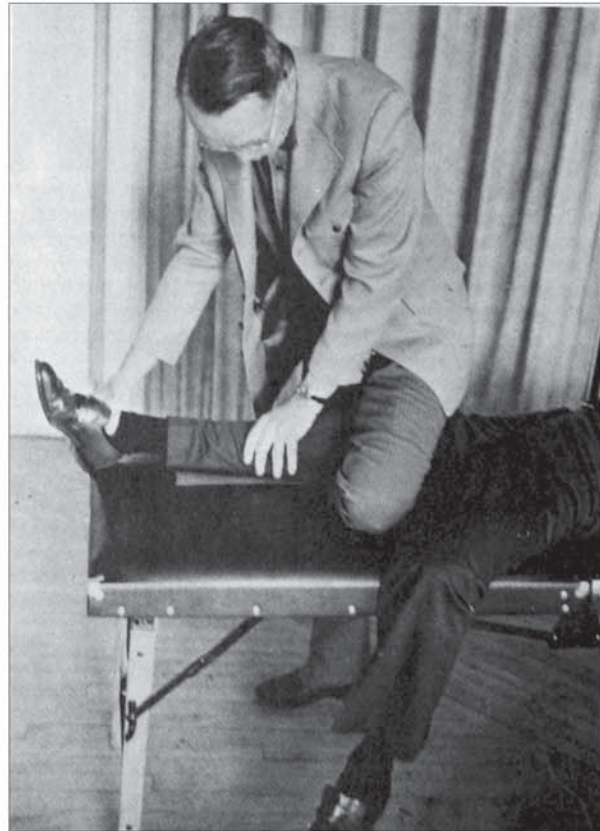

Fig. 9. Anterior cruciate ligament. Proprioceptors here are apparently in the anterior cruciate ligament. Triggers are in lower part of hamstring muscles. Knee is painful and weak in many positions. Relief is obtained by a marked shearing force (as much as 50 pounds, if it is not painful). Photo shows force achieved by operator placing his own calf beneath distal femur head of the patient. Proximal head of the tibia is then pushed backward in relation to femur. The tibia is usually internally rotated on femur. If this common problem is undiscovered, it can result in a large portion of knee treatment failures.

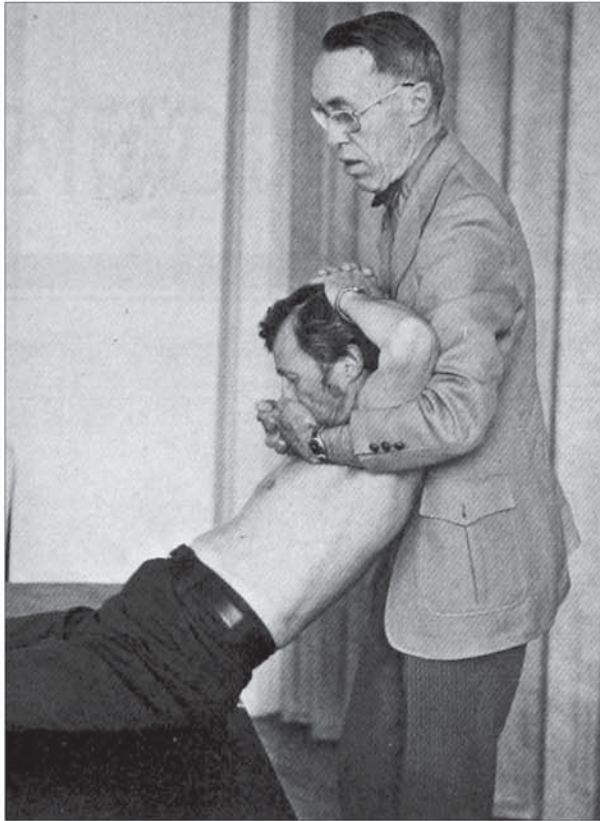


Fig. 11. Anterior thoracic. Sensitive trigger is in presternal notch. This is an easy method of achieving marked antexion of spine at level of 1st thoracic. It has the disadvantage that operator's hands are too busy to check on relief of tenderness in presternal notch. However, the technique seldom fails. This release is often followed by spontaneous release of tension over elevated 1st rib. If not, it is followed by Fig. 12. It should always be checked before correcting the elevated 1st rib.

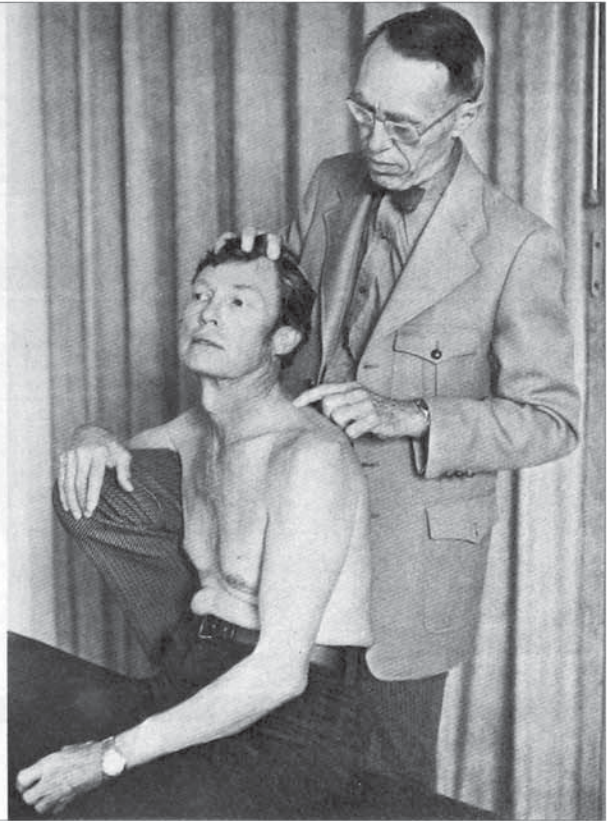


Fig. 12. Elevated 1st rib. Surprisingly simple and easy relief for elevated first rib. Neck is slightly side-bent away, postexed, and rotated toward rib. Opposite arm rests over knee of operator.

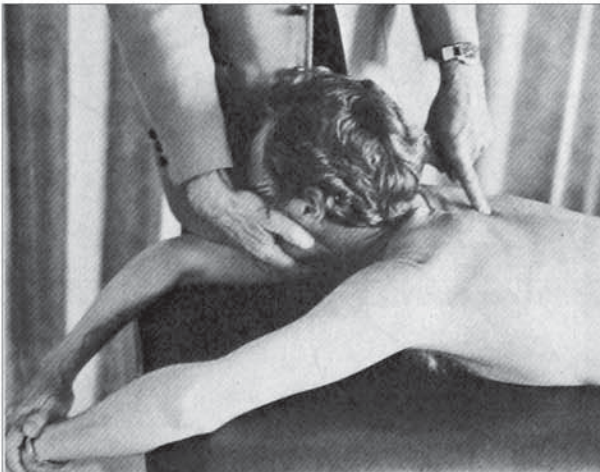

Fig. 13. Posterior 3rd thoracic. Trigger close to midline on spinous process of 3rd thoracic vertebra. Relieved in postexion. Rotation usually away and slight side-bending away from painful side. Similar techniques effective for the 4th, 5th, and 6th thoracic joints.

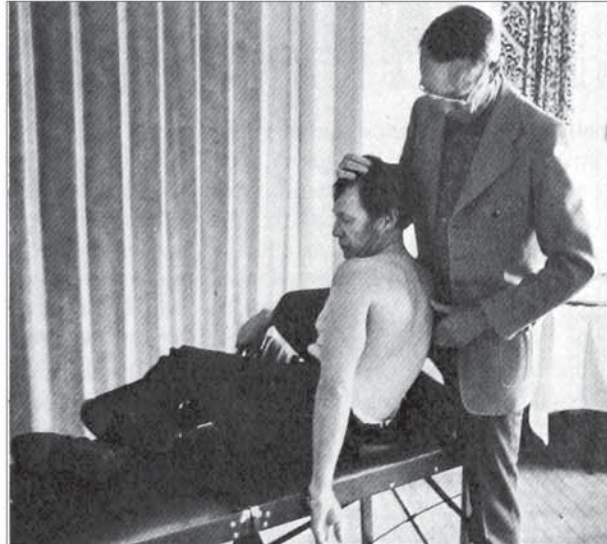

Fig. 14. Elevated 4th rib right. Patient seated on table leans to the right over operator's thigh and brings his own feet onto the table beside him. Stretch at 4th thoracic level is left side-bending and rotation left. Release as in all sitting positions is delayed about 30 seconds because patient feels less secure than he does lying flat. This technique is effective for elevated ribs 2nd thru 8th. Triggers very common and sharp are located on the angles of the ribs.

applications received for the 1975-6 Public Health Service Scholarships came from the Kansas City College of Osteopathic Medicine. The school's students submitted 96 applications, the most received from any of the nation's 114 medical and nine osteopathic schools. KCCOM already ranks first in participation, with 66 PHS scholarship holders out of a U.S. total of 1,845.

Four D.O. schools and the District of Columbia's three M.D. schools are among the top 11 schools in submitting applications. Ranking eighth is the Kirksville College of Osteopathic Medicine, with 40 applicants and 36 participants; ninth is the College of Osteopathic Medicine and Surgery of Des Moines, with 37 applicants and 23 participants; and eleventh is the Philadelphia College of Osteopathic Medicine, with 33 applicants and 27 participants.

This is an outstanding showing in this particular program by our college of osteopathic medicine.

Results of a recent study by the National Cancer Institute of Italy, which seem to demonstrate the value of a three-drug combination therapy after breast cancer surgery, appear to be nothing short of spectacular. In an editorial written for *The New England Journal of Medicine*, the distinguished American cancer specialist Dr. James Holland of Mount Sinai School of Medicine states that the conclusions developed from the study "can be accepted with confidence."

The Italian researchers used cyclophosphamide, methotrexate, and fluorouracil, a combination called CMF, in a controlled study of female patients who were found to have lymph node metastases resulting from a primary breast cancer. After 27 months of study, only 5.3 percent of women receiving CMF chemotherapy had recurrence of the disease, while 24 percent of the control patients had recurrence.

Although the authors urged caution in interpreting their results, it appears that a major break-

through has occurred.

In *The New England Journal of Medicine* editorial Dr. Holland writes, "Much research remains to be done . . . but this fact should not impede the adoption of the treatment by qualified physicians for patients who cannot participate in this research." It has been described by competent observers that it is "a work of monumental importance." All that we can say is that we sincerely hope so.

In a recent letter from John G. Bellows, M.D., Ph.D., editor of *Comprehensive Therapy*, a journal for continuing medical education, compliments were made concerning the fine quality of THE JOURNAL OF THE AMERICAN OSTEOPATHIC ASSOCIATION. The executive/editorial committee of *Comprehensive Therapy* includes Michael DeBakey, M.D., president; Morris Fishbein, M.D., chairman; Leon O. Jacobson, M.D., vice-chairman; and John G. Bellows, M.D., director and editor.

Comprehensive Therapy is the official publication of the American Society of Contemporary Medicine and Surgery. It is one of the finest quality journals to come across the AOA Editorial desk. Members of our Association who are interested in this journal should direct their inquiry to *Comprehensive Therapy*, 30 North Michigan Avenue, Chicago, Illinois 60602.

Kenneth L. Ettenson, long-time Treasurer of the American Osteopathic Association, retired on February 1, 1976. Mr. Ettenson served the profession for more than 19 years. Bernard A. Czarnowski has been appointed by the AOA Board of Trustees to the position of Controller. Mr. Czarnowski received his B.S. and M.B.A. degrees in accounting at De Paul University in Chicago. He was previously employed as Controller of the Archdiocese of Chicago, Catholic School Board.